

Case Report of a Rare Multiple-Torsion of Left Adnexa with Necrotic Hematosalpinx and Ovarian Fibroma with Extensive Hemorrhage in a 69-Year-Old Postmenopausal Woman: Diagnostic Challenges in Menopause

ARTICLE INFO

DOI: 1052547/sjrm.11.1.5

Editorial

Article Type

Meta-Analysis

Authors

Franaz Nami^{1*}, Maryam Sanaye Naderi^{1,2}, Hadis Mohamadian¹, Mostafa Ghaharzadeh Mahabadi³

1- Sarem Gynecology, Obstetrics and Infertility Research Center, Sarem Women's Hospital, Iran University of Medical Science (IUMS), Tehran, Iran.

2- Sarem Cell Research Center (SCRC), Sarem Women's Hospital, Tehran, Iran.

3- Department of Public Administration, Payame Noor University, Tehran, Iran.

*Corresponding Authors:

Franaz Nami; Sarem Fertility & Infertility Research Center (SAFIR), Sarem Women's Hospital, Iran University of Medical Sciences (IUMS), Tehran, Iran.

Address: Sarem Women Hospital, Basij Square, Phase 3, Ekbatan Town, Tehran, Iran. Postal code: 1396956111, Phone: +98 (21) 44670888, Fax: +98 (21) 44670432.

Received: 08 May 2026

Accepted: 23 May 2026

Published: 18 June 2026

Article History

Background: Adnexal torsion in postmenopausal women is rare and its diagnosis is often delayed. This report presents a rare case of multiple-turn torsion of the left adnexa in a 69-year-old postmenopausal woman with a 17-year history of no medical follow-up.

Case Presentation: A 69-year-old woman (G2L2) with a history of two cesarean sections and abdominoplasty presented with acute abdominal pain after 17 years without any medical check-up since menopause. Ultrasonography revealed a right ovarian cyst (95×72×71 mm) and a left uterine fibroid (75–103 mm). MRI demonstrated an anterior-lateral uterine mass (170×127 mm) suggestive of a degenerated fibroid. Tumor markers were within normal limits. During laparoscopy, the left adnexa showed 3–4 turns of torsion accompanied by necrosis and severe hemorrhage. Left salpingo-oophorectomy was performed, and intraoperative frozen section confirmed a benign fibroma. Subsequently, total hysterectomy with right salpingo-oophorectomy was carried out. Final pathology revealed right ovarian fibroma with extensive hemorrhage, serous cystadenoma, and severe necrotic-hemorrhagic hematosalpinx secondary to torsion.

Conclusion: Ovarian torsion can occur even in advanced postmenopausal age (69 years) and in completely benign masses. A 17-year lack of follow-up after menopause was the main factor contributing to delayed diagnosis. Timely laparoscopic surgery using intraoperative frozen section represents a standard and effective approach. This case highlights that adnexal torsion should be considered in any postmenopausal woman presenting with acute abdominal pain and a pelvic mass, even at advanced age.

Keywords: Postmenopausal Adnexal Torsion, Ovarian Fibroma, Necrotic Hematosalpinx, Serous Cystadenoma.

Introduction

Adnexal torsion is considered a relatively common gynecological emergency and refers to the rotation of the ovary, and sometimes the fallopian tube, around its vascular pedicle (infundibulopelvic ligament). This condition leads to impairment of venous and subsequently arterial blood flow, resulting in edema, ischemia, necrosis, and ultimately loss of the affected organ^[1, 2]. Epidemiologically, adnexal torsion most commonly occurs in women of reproductive age, with approximately 80–90% of cases reported between the second and fourth decades of life, and a mean age of 25–35 years.

In contrast, adnexal torsion in postmenopausal women is a rare phenomenon. According to systematic reviews, less than 3–5% of all torsion cases occur in postmenopausal women. This low incidence is largely attributed to the physiological atrophy of the ovaries after menopause and the marked reduction in their size and functional activity. However, rarity does not imply impossibility, and several case reports have documented ovarian torsion in women aged 60–80 years, although occurrence in the seventh decade of life (such as 69 years) remains exceptional^[3–5].

The pathophysiology of adnexal torsion in postmenopausal women differs significantly from that in reproductive-aged women. In younger women, torsion often occurs in otherwise normal ovaries or those containing small functional cysts, frequently influenced by hormonal stimulation. In contrast, in postmenopausal women, due to the absence of cyclic ovarian activity, almost all cases of torsion are associated with a space-occupying lesion within the ovary. Such a mass acts as a “dangling weight,” creating imbalance in the ovarian center of gravity and predisposing it to rotation around its vascular axis. The size of the mass plays a crucial role in this mechanism^[4, 6, 7].

Evidence suggests that masses measuring 5–10 cm in diameter carry the highest risk of torsion. Smaller masses (<5 cm) typically lack sufficient weight to induce torsion, whereas larger masses (>10 cm) are often stabilized within the pelvis due to adhesions to adjacent structures such as the omentum or bowel, reducing their likelihood of torsion. Histopathologically, the most commonly reported masses associated with torsion in postmenopausal women include ovarian fibroma, serous and mucinous cystadenomas, mature cystic teratomas, and less frequently, low-grade malignant tumors such as borderline ovarian tumors^[8–10].

One of the most critical challenges in managing adnexal torsion in postmenopausal women is delayed diagnosis. Unlike reproductive-aged women, who typically present with sudden onset of severe unilateral pelvic pain accompanied by nausea and vomiting, elderly postmenopausal women often exhibit vague,

subacute, and nonspecific symptoms. These may include dull and chronic pelvic or lower abdominal pain that gradually worsens, abdominal bloating, mild nausea, anorexia, changes in bowel habits, and occasionally low-grade fever^[10, 11].

Such nonspecific symptoms can easily be mistaken for more common conditions in the elderly population, including irritable bowel syndrome (IBS), diverticulitis, gastroenteritis, renal colic, or even degenerative spinal disorders. Consequently, many patients initially seek care from gastroenterologists, urologists, or general practitioners, leading to a loss of the critical window for ovarian salvage before irreversible necrosis occurs. Studies have shown that the diagnostic delay in postmenopausal women with torsion is, on average, 3–7 days longer than in reproductive-aged women. This delay often results in diagnosis at advanced stages of ischemia and irreversible necrosis, as observed in our patient, who presented with a completely necrotic fallopian tube and severe hematosalpinx^[12–15].

Perhaps the most notable and debatable aspect of this case is the patient’s 17-year history of complete absence of medical follow-up after menopause. According to international guidelines (such as ACOG, RCOG, and FIGO), all postmenopausal women are recommended to undergo regular (typically annual) pelvic examinations and transvaginal ultrasonography. The primary aim of such follow-up is early detection of ovarian masses before complications such as malignancy or torsion occur. Unfortunately, a common misconception among postmenopausal women is that medical consultation is no longer necessary after cessation of menstruation and the end of reproductive age. This misconception can lead to serious consequences, as demonstrated in this case. In our patient, an ovarian fibroma and a serous cystadenoma likely remained undetected in the pelvis for several years, gradually increasing in size until they became sufficiently heavy to cause 3–4 complete turns of torsion. Had the patient undergone even a single ultrasound examination during these 17 years, the masses could have been detected earlier, and torsion, being a preventable complication, might have been avoided.

This case clearly illustrates that lack of postmenopausal follow-up is an independent and significant risk factor for acute complications of pelvic masses and should be addressed in public health education campaigns.

From a surgical management perspective, one of the major intraoperative challenges in postmenopausal women with adnexal torsion is determining the appropriate extent of surgery. Given that the risk of malignancy in ovarian masses increases after menopause (although tumor markers were normal in this case), surgeons must choose between two approaches: (a) conservative surgery involving removal of only the affected adnexa (unilateral

salpingo-oophorectomy), or (b) comprehensive surgery including total hysterectomy with bilateral salpingo-oophorectomy. In this context, intraoperative frozen section analysis plays a crucial role. Frozen section involves rapid pathological examination of the specimen during surgery at temperatures of -20 to -30°C , providing diagnostic information within 20–30 minutes regarding the benign or malignant nature of the mass. In our patient, left salpingo-oophorectomy was first performed, and frozen section confirmed a benign fibroma. Based on this result, the surgeon proceeded with total hysterectomy and removal of the contralateral adnexa. If malignancy had been reported, the surgical approach would have shifted toward full staging, including omentectomy and lymph node sampling. Therefore, frozen section is considered a gold standard in the surgical management of ovarian masses in postmenopausal women. In summary, this case is noteworthy and worthy of publication for several reasons: (1) the advanced age of the patient (69 years), representing the upper spectrum of reported cases; (2) the high degree of torsion (3–4 complete turns), which is relatively rare and typically associated with severe necrosis; (3) the unusual pathological combination of ovarian fibroma with extensive hemorrhage, serous cystadenoma, and concurrent necrotic-hemorrhagic hematosalpinx; (4) the presence of severe hematosalpinx as a rare complication of benign masses; and (5) the exceptionally long interval (17 years) without follow-up after menopause, clearly demonstrating the impact of neglecting routine care. The aim of this case report is to increase awareness among gynecologists, general surgeons, and family physicians regarding the possibility of adnexal torsion in elderly postmenopausal women (even those over 65 years). It also emphasizes the importance of educating postmenopausal women about regular follow-up and annual ultrasound screening. Furthermore, this report provides a practical example of successful laparoscopic management using frozen section in a high-risk patient with prior surgical adhesions (history of cesarean section and abdominoplasty).

Case Presentation

A 69-year-old woman was admitted to Sarem Super Specialty Hospital in Tehran under the care of her attending physician. She was gravida 2, para 2 (G2L2), with a history of two previous cesarean sections and prior abdominoplasty. The patient had not undergone any medical evaluation or routine check-up during the 17 years following menopause. She presented with acute abdominal pain approximately 10–14 days prior to surgery.

On September 13, 2025, transabdominal ultrasonography revealed a right ovarian cyst measuring $95 \times 72 \times 71$ mm and a uterine fibroid measuring 75–103 mm on the left side of the uterus. Subsequently, magnetic resonance imaging (MRI) performed on September 11, 2025 demonstrated a

large anterior-lateral uterine mass measuring 170×127 mm, suggestive of a degenerated fibroid. All tumor markers were reported within normal limits. Laparoscopic surgery was performed on September 28, 2025. Intraoperatively, two large adjacent masses were identified in the left adnexa, causing 3–4 complete turns of torsion. The left fallopian tube and the larger mass exhibited necrotic changes. Following adhesiolysis and detorsion, the large ovarian mass along with the left fallopian tube was removed and sent for intraoperative frozen section analysis. The frozen section result was consistent with a benign fibroma.

Based on this finding, the surgical procedure was continued with total hysterectomy and right salpingo-oophorectomy. Final histopathological evaluation revealed an ovarian fibroma with extensive hemorrhage in the right ovary, a serous cystadenoma, and severe hematosalpinx with necrotic and hemorrhagic changes in the left fallopian tube secondary to torsion.

This case represents a rare instance of ovarian torsion occurring in a postmenopausal woman, which had remained undiagnosed due to the presence of ovarian masses and the absence of routine medical follow-up. The therapeutic interventions included diagnostic ultrasonography, tumor marker evaluation (all within normal range), diagnostic-therapeutic laparoscopy, adhesiolysis and detorsion, left salpingo-oophorectomy, intraoperative frozen section analysis (benign result), total hysterectomy, and right salpingo-oophorectomy. Given the patient's advanced age (69 years), the presence of 3–4 turns of torsion, necrotic hematosalpinx, and the pathological findings (fibroma with extensive hemorrhage and serous cystadenoma), this case is considered rare and valuable for publication.

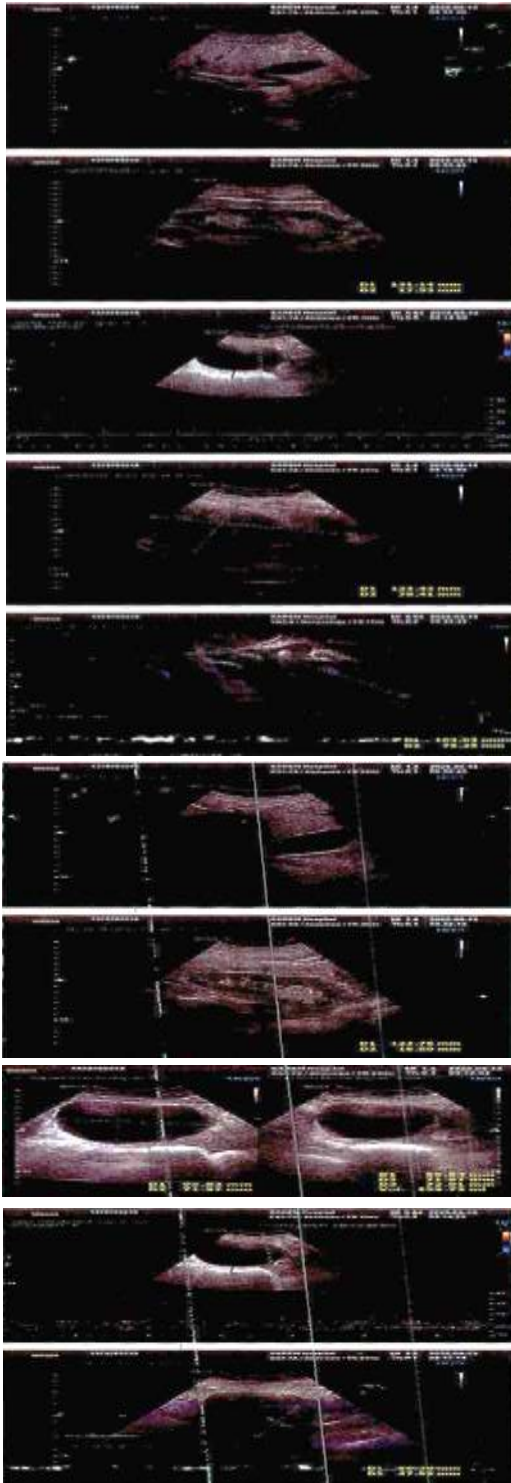


Figure 1: Color Doppler ultrasonography of the pelvis demonstrates a large right ovarian cyst (dimensions 95×72×71 mm) and a fibroid mass in the left side of the uterus. Color Doppler flow study has been performed.

Discussion

Adnexal torsion is a gynecological emergency that, although common in women of reproductive age, is rare in postmenopausal women and is often diagnosed

with delay due to its nonspecific clinical presentation [16,17]. The pathophysiology of torsion in postmenopausal women is almost invariably associated with the presence of ovarian masses, most of which are benign, such as fibromas and cystadenomas. Lack of regular postmenopausal follow-up represents one of the most important preventable risk factors for the development of this condition. In the present case, a 69-year-old postmenopausal woman with a 17-year history of no medical follow-up developed 3–4 turns of left adnexal torsion accompanied by necrotic hematosalpinx and ovarian fibroma with extensive hemorrhage. Tumor markers were within normal limits, and intraoperative frozen section confirmed the benign nature of the lesion.

This case report is significant for several reasons. First, it demonstrates that ovarian torsion can occur even in advanced postmenopausal age (69 years) and in completely benign masses. Therefore, clinicians should always consider adnexal torsion in the differential diagnosis of any postmenopausal woman presenting with acute abdominal pain and a pelvic mass. Second, the patient's 17-year absence of medical follow-up highlights the critical importance of educating postmenopausal women about the necessity of annual examinations and regular ultrasonographic screening. Third, the successful laparoscopic management using intraoperative frozen section provides a practical model for treating similar high-risk patients, particularly those with prior surgical adhesions. Fourth, the rare pathological combination (ovarian fibroma with extensive hemorrhage, serous cystadenoma, and necrotic hematosalpinx) further enhances the educational and archival value of this report. Finally, this case serves as a warning against the common misconception that medical follow-up is unnecessary after menopause.

Marwaha et al. (2023) reported a case of ovarian torsion in a 73-year-old postmenopausal woman with a 20-year history of menopause and no significant medical or surgical history [4]. Their patient presented with acute abdominal pain of 4 hours' duration and one episode of vomiting. Ultrasonography revealed a large anechoic cyst (volume: 3181 mL) in the right adnexa with absent vascular flow on color Doppler. Intraoperatively, four complete turns of torsion of the right ovary were observed. Due to the lack of access to frozen section analysis, total abdominal hysterectomy with bilateral salpingo-oophorectomy was performed. Final pathology confirmed serous cystadenoma.

Compared to the study by Marwaha et al., our patient was also an elderly postmenopausal woman (69 years) with 3–4 turns of adnexal torsion, showing notable similarities in age and degree of torsion. However, several important differences exist. First, our patient had a 17-year history of no follow-up and prior surgical history (two cesarean sections and

abdominoplasty), whereas the patient in Marwaha's study had no significant medical or surgical history. Second, our case demonstrated a more complex pathological profile, including fibroma with extensive hemorrhage, serous cystadenoma, and necrotic hematosalpinx, while only serous cystadenoma was reported in their case. Third, intraoperative frozen section was utilized in our case, allowing confirmation of benign pathology prior to definitive surgical decision-making; in contrast, lack of this facility in Marwaha's study necessitated complete surgery without prior knowledge of the lesion's nature. Fourth, the diagnostic delay in our patient (10–14 days) was significantly longer than in their case (4 hours), likely due to more subtle symptoms and delayed presentation. These differences suggest that prior surgical history (and adhesions) may alter the clinical presentation of torsion and highlight the importance of frozen section availability in optimizing surgical management.

Tjokropawiro et al. (2023) described a 62-year-old postmenopausal woman presenting with acute pelvic pain [18]. Computed tomography revealed a large ovarian cystic mass measuring $15.1 \times 10.2 \times 11.2$ cm with thick septations and multiple mural nodules. The patient's CA-125 level was within normal limits. During exploratory laparotomy, 100 mL of hemorrhagic ascites was noted. Gross examination showed an ovarian cyst with necrosis and hemorrhage weighing 830 g and measuring $15 \times 12 \times 8$ cm. Final histopathology confirmed serous cystadenoma. The authors concluded that in elderly women with acute lower abdominal pain, ovarian torsion should be suspected, and that a complex cystic mass with normal CA-125 levels is more suggestive of benign torsion than malignancy.

Our case shares several similarities with the report by Tjokropawiro et al., including advanced age (both over 60 years), acute abdominal pain, normal tumor markers, and ultimately benign pathology (serous cystadenoma). However, notable differences are present. The size of the mass in their study was approximately 15 cm (830 g), while in our patient the MRI-demonstrated anterior-lateral uterine mass measured approximately 17 cm; although comparable in size, the weight was not reported in our case. Imaging modalities also differed: CT in their study showed features suspicious for malignancy (thick septations and mural nodules), whereas ultrasound and MRI in our case suggested a degenerated fibroid, and multiple tumor markers (not only CA-125) were normal. Intraoperative findings in our patient revealed 3–4 complete turns of torsion with severe necrotic and hemorrhagic hematosalpinx, representing a more advanced presentation compared to the study by Tjokropawiro et al., which reported only necrosis and hemorrhage of the cyst. From a surgical management perspective, the use of intraoperative frozen section in our case enabled confident decision-making and

performance of hysterectomy with bilateral salpingo-oophorectomy, whereas no such approach was reported in their study.

Both reports emphasize that normal CA-125 levels in a postmenopausal woman with a complex adnexal mass and acute pelvic pain should not exclude the possibility of benign ovarian torsion. It is noteworthy that the patient in Tjokropawiro's study was younger (62 years) compared to our patient (69 years), and the duration of menopause was not specified, whereas our patient had 17 years of menopause without follow-up, an important risk factor. These comparisons indicate that ovarian torsion associated with benign masses can occur even in the sixth and seventh decades of life, and that tumor markers alone cannot reliably distinguish between benign and malignant lesions. Optimal management requires integration of clinical, imaging, and intraoperative findings, including frozen section when available.

Conclusion

This case report describes a 69-year-old postmenopausal woman with a 17-year history of no medical follow-up who developed 3–4 complete turns of left adnexal torsion associated with necrotic hematosalpinx, ovarian fibroma with extensive hemorrhage, and serous cystadenoma. Although ovarian torsion is rare in postmenopausal women, it can occur even in the seventh decade of life and should not be overlooked. A prolonged absence of medical follow-up represents a serious warning and underscores the need to educate postmenopausal women about the importance of annual examinations and regular ultrasonographic screening. A history of prior surgeries (cesarean section and abdominoplasty) may obscure the clinical presentation and contribute to delayed diagnosis. Normal tumor markers cannot reliably exclude benign pathology, and definitive decision-making should be based on a combination of clinical, imaging, and intraoperative findings. The successful use of intraoperative frozen section in this case further supports its value in guiding surgical management. Ultimately, regular postmenopausal follow-up, early diagnosis, and timely surgical intervention remain the key factors in preventing serious complications such as adnexal torsion and necrosis.

Ethical Issue

In conducting this research, all ethical principles in medical and biological research were observed in accordance with the Declaration of Helsinki, and the rights, dignity, and confidentiality of the participants were protected.

Conflict of Interests

There was no conflict of interest in this study.

Source of Funding

The costs of this project were funded by the Sarem Gynecology, Obstetrics and Infertility Research Center.

References

- Papillon-Smith, J. and M. Sobel, Adnexal torsion. *Cmaj*, 2018. 190(25): p. E769.
- Pourhoseini, S., N. Sabeti, and E. Hajmollarezaei, Isolated Fallopian Tube Torsion in Chronic Pelvic Pain: A Rare Case %J JRI. *Journal of Reproduction & Infertility*, 2025. 26(4): p. 255-260.
- Bandhon, B.Z., V. Rajadurai, and C. Johansson, Ovarian Torsion in Normal Ovaries in Reproductive-Aged Women. *Case Rep Obstet Gynecol*, 2025. 2025: p. 6630642.
- Marwaha, P.D., et al., Ovarian Torsion in a Postmenopausal Woman: A Case Report and Review of Literature. *J Menopausal Med*, 2023. 29(3): p. 134-138.
- Bridwell, R., A. Koyfman, and B. Long, High risk and low prevalence diseases: Ovarian torsion. *The American Journal of Emergency Medicine*, 2022. 56.
- Cohen, A., et al., Adnexal Torsion in Postmenopausal Women: Clinical Presentation and Risk of Ovarian Malignancy. *J Minim Invasive Gynecol*, 2017. 24(1): p. 94-97.
- Cunha, S., et al., Adnexal torsion in postmenopausal women: An even more challenging diagnosis. 2018: p. 48-51.
- Huang, C., M.K. Hong, and D.C. Ding, A review of ovary torsion. *Tzu Chi Med J*, 2017. 29(3): p. 143-147.
- Lawrence, A., et al., Factors Associated With Torsion in Pediatric Patients With Ovarian Masses. *Journal of Surgical Research*, 2021. 263: p. 110-115.
- Bailey, F., et al., Ovarian torsion: a modern approach to management. *The Obstetrician & Gynaecologist*, 2025. 27(3): p. 221-230.
- Shih, S., et al., Adnexal torsion. An unusual cause of abdominal pain in postmenopausal women. *The American surgeon*, 1991. 57(5): p. 327-329.
- Olden, K.W.J.C.C.j.o.m., Irritable bowel syndrome: an overview of diagnosis and pharmacologic treatment. 2003. 70(6; SUPP): p. S3-S7.
- Valtierra Oba, E.R., et al., Irritable Bowel Syndrome in the Elderly Population: A Comprehensive Review. *Cureus*, 2024. 16(8): p. e68156.
- Oba, E.R.V., et al., Irritable Bowel Syndrome in the Elderly Population: A Comprehensive Review. 2024. 16(8).
- Saha, L., Irritable bowel syndrome: pathogenesis, diagnosis, treatment, and evidence-based medicine. *World J Gastroenterol*, 2014. 20(22): p. 6759-73.
- Abdelazim, I.A., et al., Postmenopausal adnexal torsion: rare case report. *Prz Menopauzalny*, 2020. 19(1): p. 49-51.
- Ganer Herman, H., et al., Clinical characteristics and the risk for malignancy in postmenopausal women with adnexal torsion. *Maturitas*, 2015. 81(1): p. 57-61.
- Tjokroprawiro, B.A., K. Novitasari, and R.A. Ulhaq, Twisted ovarian cyst in postmenopausal woman: A case report. *International Journal of Surgery Open*, 2023. 59: p. 100681.